

Neurotoxicity of Chlorpyrifos, Carbofuran, and Cypermethrin in Adolescent Rats' Brain

Muhammad Ihwan Narwanto,¹ Azham Purwandhono,² Kristianningrum Dian Sofiana,³ Zahrah Febianti,⁴ Elvia Rahmi Marga Putri,⁵ Muhammad Afiful Jauhani⁶

¹Anatomy Department, Faculty of Medicine Jember University, Indonesia

²Pathology Anatomy Department, Faculty of Medicine Jember University, Indonesia

³Physiology Department, Faculty of Medicine Jember University, Indonesia

⁴Biochemistry Department, Faculty of Medicine Jember University, Indonesia

⁵Pathology Clinic Department, Faculty of Medicine Jember University, Indonesia

⁶Forensic Department, Faculty of Medicine Jember University, Indonesia

Abstract

Chronic exposure to insecticides, even at low levels, has led to chronic neurotoxicity. Adolescent brain is still undergoing important developments, including in the hippocampus. This study investigated neurotoxicity effects of subacute exposure to chlorpyrifos, carbofuran and cypermethrin in the brain of adolescent rats. This study was performed at the Histology, Biochemistry, and Animal House Laboratory of Jember University from November to December 2021. Subjects were divided into five groups: normal, control, chlorpyrifos, carbofuran, and cypermethrin. Short-term memory was evaluated by Y maze test and tissue damage was evaluated by histological examination. Brain MDA levels were determined by thiobarbituric acid reactive substance method to evaluate the oxidative stress effect on the organ. This study showed spontaneous alternation in the Y maze test and the number of pyramidal neurons in hippocampus decreased in the cypermethrin group. There was a significant elevation of brain MDA level in carbofuran and cypermethrin groups. Thus, cypermethrin causes more severe neurotoxicity than carbofuran and chlorpyrifos. Improvements in the insecticide application management are urgently needed to prevent neurotoxicity.

Keywords: Hippocampus, insecticide, memory, oxidative stress

Introduction

Many fields use insecticide, like agriculture, industry, and household activity. The organic synthetic insecticide group consists of organophosphate, carbamate, pyrethroid, and organochlorine substances.¹ Organophosphate plays a role by inhibiting acetylcholinesterase activity in the neural organ. One of the active substances in the organophosphate group used widely in Indonesia is chlorpyrifos.^{2,3} Like organophosphate, the carbamate group also can inhibit cholinesterase activity in the neuron. Carbofuran is one of the carbamate substances commonly used.⁴ The Pyrethroid group, like cypermethrin, has a role in neural sodium channel modulation.⁵

The insecticide is a risk factor for neurotoxicity. High doses with short-term insecticide exposure

caused acute neurotoxicity. Low doses with long-term exposure to insecticide can make substance accumulation that ends with chronic neurotoxicity.⁶ Neurotransmitter disturbance, oxidative stress, and neuroinflammation are primary mechanisms of insecticide-related neurotoxicity that can lead to a degenerative state.⁷

Naturally, human has matured brain since they were born. However, in the adolescent stage, critical development of the brain occurs in the cortex and limbic system, including the hippocampus. Anatomic changes are determined by increasing volume, thickening of grey and white matter, increasing plasticity, and synaptic remodeling.⁸ This research explores whether neurotoxicity occurs in sub-acute exposure to insecticide chlorpyrifos, carbofuran, and cypermethrin in the adolescent rat.

Corresponding Author:

Muhammad Ihwan Narwanto
Anatomy Department, Faculty of Medicine Jember
University, East Java, Indonesia
Email: muhammadnarwanto@unej.ac.id

Methods

Chlorpyrifos (Pestanal[®]), carbofuran (Pestanal[®]), and cypermethrin (Pestanal[®]) were

purchased from Sigma-Aldrich, Saint Louis, USA. Thiobarbituric acid was purchased from Tokyo Chemical Industry, Portland, USA. Other reagents and materials were obtained from the laboratory.

This study was conducted from November to December 2021 at the Histology, Biochemistry, and Animal House Laboratory of Jember University. Twenty-five male healthy Wistar adolescent rats (*Rattus norvegicus*) aged 40 days old were kept in a 12:12 light-dark cycle. Each 2 to 3 rats were kept in one cage and fed ad libitum. They were divided into five groups (n=5); normal: receiving no-treatment, control: receiving DMSO 5% subcutaneously, chlorpyrifos: receiving chlorpyrifos 20 mg/kgBW/day subcutaneously, carbofuran: receiving carbofuran 0.2 mg/kgBW/day subcutaneously, cypermethrin: receiving cypermethrin 20 mg/kg BW/day subcutaneously. The treatment lasts for 21 days. The three treatment doses are 10% LD50 doses. Y maze test was performed on the first day and the 21st day. The rats were then terminated with cervical dislocation on the 21st day after the Y Maze test and the rat's brain was removed. Furthermore, the brain MDA levels were examined and the brain histopathological preparation was carried out. This study was approved by the Health Ethics Committee of the Faculty of Medicine, University of Jember (letter no: 1547/H25.1.11/KE/2021).

The Y maze test was used to analyze the rat's short-term memory. Memory was expressed in percentage as spontaneous alternation. Spontaneous alternation was calculated as the ratio of the number of correct arms admissions to the probability of spontaneous alternation (total arm entry minus two). For example, the rat entered the Y Maze arms in this order: BCACBACABC (10 arms). Meanwhile, there were 5 correct alterations (BCA-ACB-CBA-BAC-ABC), then the percentage of spontaneous alternation was $(5/8) \times 100 = 63\%$. The minimum number of arms to be entered is 8 and is considered to be in the arms if the entire body has passed the half-arms.⁹

MDA levels were measured in g/mL using the thiobarbituric acid (TBA) method, the data were shown in percentage relative to normal. The brain tissue was weighed, then grounded in a medium containing 50 mM Tris/HCl and 300mM sucrose pH 7.4 at a ratio of 10% (w/v). The mixture was homogenized and then centrifuged at 1,400 g for 10 minutes at 4°C. The supernatant was stored at -80°C until the measurement. As much as 0.25 ml of the supernatant was mixed with 0.25 ml



Figure Illustration of Y Maze⁹

of 20% trichloroacetic acid, then centrifuged at 1,000 rpm for 4 minutes. The thiobarbituric acid (0.5 mL 0.67% in 0.026 M tris buffer) was added to the supernatant and then heat at 100°C for 15–30 minutes. The solution was placed on ice for 10 minutes and the results were read with a spectrophotometer (Thermo Spectronic, 4001/4, USA) at a wavelength of 532 nm.¹⁰

Histological preparations were made after 7 days of brain tissue fixation in 10% buffered formalin. Formalin blocks were made from the coronal section of the brain -3.8 mm from the bregma (containing hippocampus). The Cresyl violet staining procedure is as follows, we removed paraffin with xylol, put in 100%, 95%, and 70% ethanol sequentially for 5 minutes, then rinsed with distilled water. The histological preparations were painted with 0.1% cresyl violet for 10 minutes at 37°C, then put into 70%, 95%, and 100% ethanol sequentially, after adding xylol and covering with a glass deck. Microscopic (Olympus, CX21LEDFS1, Japan) observations with 400x magnification counted the number of pyramidal neurons in cornu ammonis 1 (CA1) hippocampus in 3 fields of view each. This process was using Image J. Cells were counted if the nucleus was stained clearly. The cells with darkly stained and wrinkled were not counted.

T-test was used to determine the effect of chlorpyrifos, carbofuran, and cypermethrin on short-term memory at the beginning and end of the treatment. The one-way ANOVA test followed by Tukey's HSD post hoc test was used to determine the effect of those three insecticides' exposure to brain MDA levels and the histology of the hippocampus. The significance level is 0.05 ($p < 0.05$).

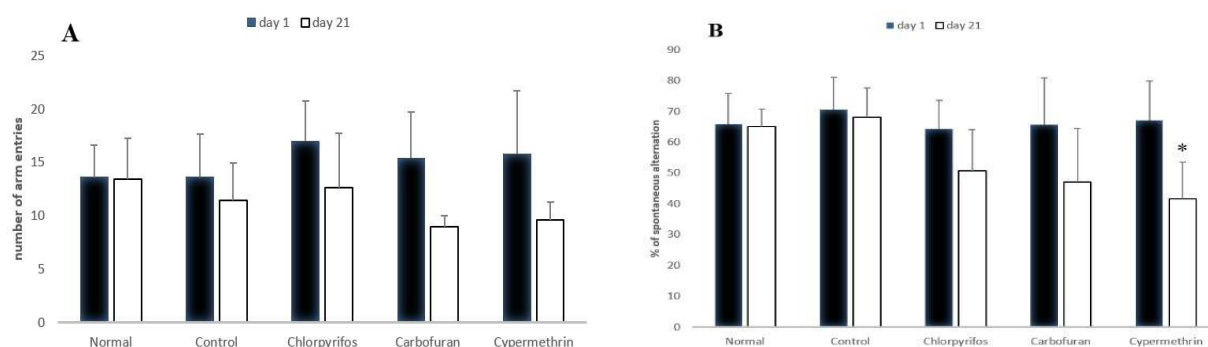


Figure 2 Effect of Insecticides Exposure on Y-maze Test

(A) The number of an entered arm, and (B) spontaneous alternation. Data was shown with mean \pm SD group on day 1 and day 21 in all groups. *) statistically significant, $p < 0.05$

Results

Spontaneous alternations and the number of the entered arm as Y maze test results on the 1st and 21st day are shown in Figure 2. It was found that the administration of the three insecticides caused a reduction in spontaneous alternation and the number of maze arms entered by rats. The cypermethrin group showed a significant decrease in spontaneous alternation on the comparison of the maze test measurements on day 1 and day 21 ($p < 0.05$).

The results of measurements of brain tissue MDA levels in each group can be seen in Figure 3. Exposure to insecticides in all treatment groups showed a tend to increase MDA levels. The carbofuran group showed a significant increase in MDA levels compared to the normal group ($p < 0.05$), and cypermethrin group showed a significant increase in MDA levels compared to the normal and control group ($p < 0.05$).

Evaluation of the number of pyramidal neurons in the CA1 hippocampus through a microscope can be seen in Figure 4A. The number of pyramidal neurons CA1 hippocampus in the cypermethrin group was less than in the normal and control group ($p < 0.05$). Furthermore, it was found pyknosis nuclear and cell degeneration in all treatment groups (Figure 4B).

Discussion

The result of the study showed that there was a neurotoxicity effect due to sub-acute exposure to the insecticides chlorpyrifos, carbofuran, and cypermethrin in the brains of adolescent rats. Neurotoxicity could be determined by the

elevation of brain MDA level, which is a marker of oxidative stress. A decrease in the number of pyramidal neurons in the CA1 hippocampus and short-term memory impairment as indicated by a decrease in spontaneous alternation in the Y maze test is also evidence of neurotoxicity. Among these groups, cypermethrin is the most significant insecticide which caused the neurotoxicity effect.

Oxidative stress in the brain due to insecticide exposure noticeably in elevation of brain MDA levels, especially in the cypermethrin and carbofuran group. This result is following a previous study about carbofuran exposure causing elevation of the MDA level in the brain.¹¹ Cypermethrin exposure in oral route with 25.089 mg/kg for 4 weeks also made elevation brain MDA level.¹² In vitro cypermethrin study

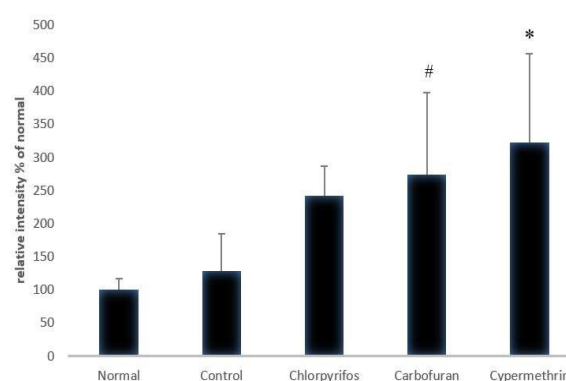


Figure 3 Brain MDA Level

MDA level in all groups, shown by mean \pm SD. #) statistically significant compared with the normal group, *) statistically significant compared with the normal and control group ($p < 0.05$).

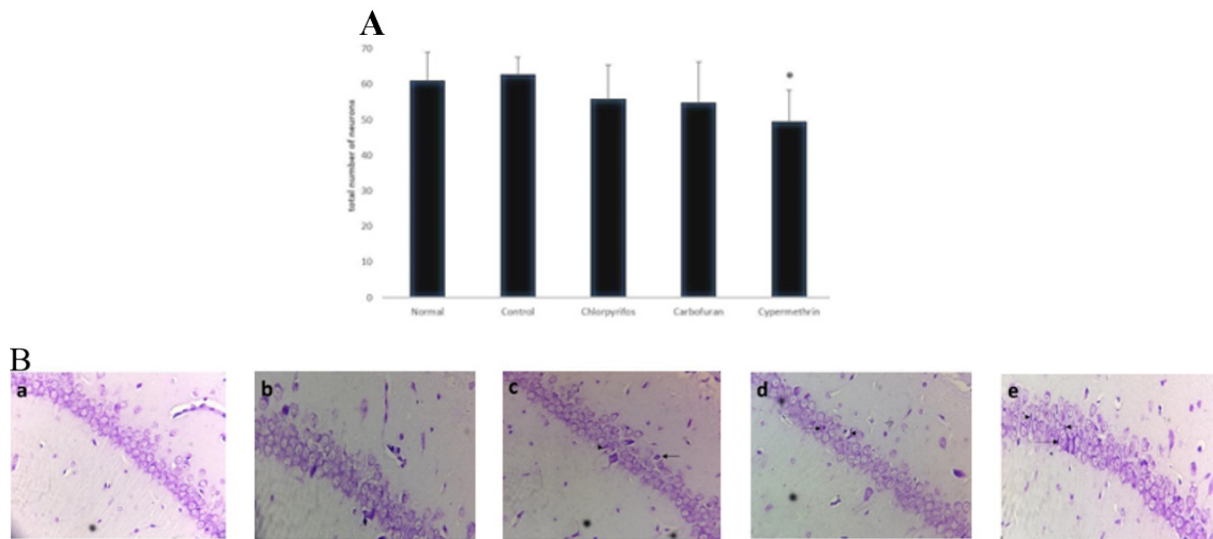


Figure 4 Histology Hippocampus

(A) The number of pyramidal neurons in the CA1 hippocampus is shown by mean±SD in each group. (*) statistically significant compared with the normal and control group, ($p < 0.05$). (B) Histology image of rat CA1 hippocampus with cresyl violet staining, 400x magnification. Pyknosis degeneration in pyramidal neurons occurred in all treatment groups (arrow). (a) normal group, (b) control group, (c) chlorpyrifos group, (d) carbofuran group, (e) cypermethrin group.

showed increased production of reactive oxygen species (ROS). Administration of cypermethrin or carbofuran could inhibit the activity of antioxidant enzymes; catalase, glutathione, and superoxide dismutase.^{11,13,14} These findings were one of the possible reasons for the occurrence of oxidative stress in brain tissue due to exposure to carbofuran and cypermethrin, resulting in an increase in MDA levels in brain tissue. In this study, the elevation of the MDA level of the chlorpyrifos group was not statistically significant. Compared to a previous study by Ibrahim, chlorpyrifos exposure duration in our study was shorter than their study that exposed their treatment group to chlorpyrifos for 4 weeks.¹² They showed that chlorpyrifos exposure for 4 weeks could increase the MDA level in the brain.

This study showed histological changes in the CA1 hippocampus due to cypermethrin exposure, such as a decrease in pyramidal neuron number, pyknosis, and neuronal degeneration. This finding is in line with other studies that cypermethrin oral exposure at a dose of 150 mg/kg (medium dose) and 300 mg/kg (high dose, approaching LD_{50}) for 28 days caused neuronal pyknosis in the brain.¹⁵ Another study stated that oral administration of cypermethrin at a dose of 12 mg/kg to pregnant and lactating rats caused neuronal damage in the medulla oblongata

indicated by chromatolysis and pyknosis.¹⁶ These histological changes can be due to oxidative stress, indicated by an increase in brain MDA levels. The subcutaneously given cypermethrin will be distributed and accumulate in the brain. Because of its small molecular weight, it will easily pass through the blood-brain barrier. The presence of cypermethrin in brain tissue will be considered a toxic agent so it will trigger oxidative stress; increased ROS production and inhibition of antioxidant enzymes in brain tissue. These all will cause cellular damage, and in the end can cause neuronal death.¹⁴ Apart from oxidative stress, neuronal death can be induced by astrogliosis and microgliosis processes. Astrogliosis and microgliosis will trigger the production and release of proinflammatory cytokines which cause neuronal damage.¹⁷ In the chlorpyrifos and carbofuran groups, neuronal degeneration and pyknosis were seen. The decrease in pyramidal neuron number in the two groups was starting to be seen. This result was in line with other studies, chlorpyrifos exposure at a dose of 16.32 mg/kg for 4 weeks caused degeneration and pyknosis in rat cerebral cortex neurons.¹² Meanwhile, carbofuran exposure to pregnant rats resulted in a reduction in the number of hippocampal neurons in the embryos.¹⁸

The results of this study showed that

insecticides exposure, especially cypermethrin, impaired rat's short-term memory, indicated by a decrease in spontaneous alternation during the Y maze test of the post-exposure group compared to the pre-exposure group. These results were supported by other studies which use cypermethrin at a dose of 25 mg/kg for 6 weeks in rats and caused memory impairment.¹⁹ Rats with a good memory will remember well the previously visited Y maze arms. The rats tend to enter the infrequently-visited Y maze arms. This was indicated by the high value of the presentation of spontaneous alternation; the higher the value of spontaneous alternation, the better the function of short-term memory.²⁰ Hippocampus CA1 in mice plays an important role in the formation of short-term memory and conversion to long-term memory.²¹ From these prior studies, it can be suspected that a reduction in the number of pyramidal CA1 neurons in the hippocampus is one of the causes of short-term memory disorders in the cypermethrin group. Another possible cause is due to oxidative stress in the brain due to the increase in ROS production. This phenomenon was characterized by an increased level of MDA. ROS will transmute to H₂O₂. It passes through the neuron membrane and activates the signaling of extracellular signal-regulated kinase and calcium calmodulin kinase II. When the signaling is activated, it disrupts protein synthesis for synaptic function.²² An excessive amount of ROS will interfere with long-term potentiation as the basis for memory formation.²³ Other assumptions regarding the possibility that underlies the memory disorders were the presence of a neuroinflammatory process and the formation of amyloid beta and tau protein. These proteins contribute to long-term potentiation disorders.¹⁹ In the chlorpyrifos and carbofuran groups, memory impairment was starting to be seen. The limitation of this study is that the concentration of cypermethrin, carbofuran, and chlorpyrifos in the brain tissue was not measured. The conclusion of this study is that cypermethrin causes impaired memory, increased MDA brain level, decreased amount of pyramidal neurons, and induced structure damage in the hippocampus of adolescent rats. Cypermethrin is a neurotoxic agent that is quite strong when compared to carbofuran and chlorpyrifos. It is necessary to study more extensively the neurotoxic effects of insecticides so that their management and prevention can be carried out properly.

References

1. Akashe MM, Pawade U V, Nikam A V. Classification of pesticides: a review. *Int J Res Ayurveda Pharm.* 2018;9(4):144–50.
2. Nining E, Sjarief R, Nazli S. Profil residu insektisida organofosfat di kawasan produksi bawang merah (*allium ascalonicum* L.) Kabupaten Brebes Jawa Tengah. *J Nat Resour Environ Manag.* 2019;9(4):999–1009.
3. Damaiyanti D, Yulianty R, Marzuki A, Kasim S, Rante H. Analisis residu pestisida klorpirifos pada cabai (*capsicum* sp.) dari Desa Bungin Kecamatan Bungin Kabupaten Enrekang. *Maj Farm dan Farmakol.* 2020;23(3):106–8.
4. Hartini E. Kontaminasi residu pestisida dalam buah melon (studi kasus pada petani Di Kecamatan Penawangan). *J Kesehat Masy.* 2014;10(1):96–102.
5. Widawati M, Kusumastuti NH. Insektisida rumah tangga dan keberadaan larva aedes aegypti di Jakarta Selatan. *ASPIRATOR J Vector-borne Dis Stud.* 2017;9(1):35–42.
6. Islam A, Malik MF. Toxicity of pesticides on CNS. *J Toxicol Anal.* 2018;1(1):7.
7. Guignet M, Dhakal K, Flannery BM, Hobson BA, Zolkowska D, Dhir A, et al. Persistent behavior deficits, neuroinflammation, and oxidative stress in a rat model of acute organophosphate intoxication. *Neurobiol Dis.* 2020;133:104431.
8. Konrad K, Firk C, Uhlhaas PJ. Brain development during adolescence. *Dtsch Arztebl Int.* 2013;110(25):425–31.
9. Fasrini UU, Susanti R, Lipoeto NI. Efek gambir (*Uncaria gambir*/Hunter Roxb) terhadap aktivitas lokomotor dan neurokognitif pada tikus betina model Alzheimer. *Neurona.* 2017;35(1):17–23.
10. Narwanto MI, Rahayu M, Soeharto S, Nurdiana, Widodo MA. Neuroprotective potency of Tamarindus indica seed extract for preventing memory impairment in rat model of alzheimer's disease. *Res J Pharm Technol.* 2020;13(9):4041.
11. Jaiswal SK, Sharma A, Gupta VK, Singh RK, Sharma B. Curcumin mediated attenuation of carbofuran induced oxidative stress in rat brain. *Biochem Res Int.* 2016;2016:7637931.
12. Abd El-Moneim Ibrahim K, Mohamed Abdelrahman S, K A Elhakim H, Ali Ragab E. Single or combined exposure to chlorpyrifos and cypermethrin provoke oxidative stress and downregulation in monoamine oxidase and acetylcholinesterase gene expression of the rat's brain. *Environ Sci Pollut Res.*

- 2020;27(11):12692–703.
13. Singh R, Firdous S, Sharma P. Neurotoxic effect of cypermethrin and protective role of resveratrol in Wistar rats. *Int J Nutr Pharmacol Neurol Dis.* 2014;4(2):104.
 14. Huang F, Liu Q, Xie S, Xu J, Huang B, Wu Y, et al. Cypermethrin induces macrophages death through cell cycle arrest and oxidative stress-mediated JNK/ERK signaling regulated apoptosis. *Int J Mol Sci.* 2016;17(6):885. doi:10.3390.
 15. Sayim F, Karabay Yavaşoğlu NÜ, Uyanıkgil Y, Aktuğ H, Yavaşoğlu A, Turgut M. Neurotoxic effects of cypermethrin in Wistar rats: A haematological, biochemical and histopathological study. *J Heal Sci.* 2005;51(3):300–7.
 16. Al-Gholam MA, Issa NM. Effect of cypermethrin on the postnatal development of the medulla oblongata and the possible protective role of melatonin in albino rats. *Anat Cell Biol.* 2020;53(4):460–70.
 17. Hassouna I. Transplacental neurotoxicity of cypermethrin induced astrogliosis, microgliosis and depletion of let-7 miRNAs expression in the developing rat cerebral cortex. *Toxicol Rep.* 2020;7:1608–15.
 18. Mishra D, Tiwari SK, Agarwal S, Sharma VP, Chaturvedi RK. Prenatal carbofuran exposure inhibits hippocampal neurogenesis and causes learning and memory deficits in offspring. *Toxicol Sci.* 2012;127(1):84–100.
 19. Maurya SK, Mishra J, Abbas S, Bandyopadhyay S. Cypermethrin stimulates GSK3 β -Dependent A β and p-tau proteins and cognitive loss in young rats: reduced HB-EGF Signaling and Downstream Neuroinflammation as Critical Regulators. *Mol Neurobiol.* 2016;53(2):968–82.
 20. Kraeuter A, Guest PC, Sarnyai Z. The Y-Maze for assessment of spatial working and reference memory in mice. *Methods in Molecular Biology.* 2019;1916:105–11.
 21. Sakaguchi Y, Sakurai Y. Left-right functional difference of the rat dorsal hippocampus for short-term memory and long-term memory. *Behav Brain Res.* 2020;382:112478.
 22. Beckhauser TF, Francis-Oliveira J, De Pasquale R. Reactive oxygen species: physiological and physiopathological effects on synaptic plasticity. *J Exp Neurosci.* 2016;10(Suppl 1):23–48.
 23. Massaad CA, Klann E. Reactive oxygen species in the regulation of synaptic plasticity and memory. *Antioxidants Redox Signal.* 2011;14(10):2013–54.