

Clinical Profile of Mucormycosis during the Second Wave of COVID-19 in a Tertiary Care Center in India

Sunil Kumar Kunhiparambath,¹ Beena Oommen,¹ Sajeeth Kumar Keeriyatt Govindan,² Karichery Shilpa Nair,¹ Sagesh Madayambath¹

¹Department of ENT, Government Medical College Kozhikode, Kerala, India

²Department of Gen Medicine, Government Medical College Kozhikode, Kerala, India

Article History

Received: November 03, 2022

Accepted: March 13, 2023

Published: March 30, 2023

DOI: 10.15850/ijhs.v11n1.3073

IJHS. 2023;11(1):20-26

Correspondence:

Sagesh M.

Department of ENT, Government
Medical College Kozhikode,
Kerala, India

E-mail: drsageshm@gmail.com

Abstract

Objective: To study the clinical profile and treatment outcome of mucormycosis associated with the second wave of COVID-19 pandemic.

Methods: An observational study was conducted in a tertiary care center over a period of 12 months, including a 6-month post treatment follow up. Study included all COVID positive patients with a clinical and radiological evidence of rhino-orbito-cerebral mucormycosis during the second wave of COVID-19. All patients underwent further diagnostic workups and confirmed cases underwent surgical debridement, and Amphotericin B was started.

Results: A total of 59 patients presented with mucormycosis with the mean age being 52.7 years with unilateral facial and orbital edema as the most common symptoms (28.8%). All were diabetic with HbA1c >7 (54.2%). The mean duration of presentation was 20.7±7.9 days from the onset of COVID-19 infection. Unilateral involvement of the paranasal sinuses was the most common finding in MRI. Early administration of Amphotericin B with prompt surgical debridement was performed in all cases. Orbital exenteration was conducted in nine patients for better fungal load clearance. Patients showed a good response to surgical debridement and prompt medical treatment, with a mortality rate of 27%.

Conclusion: COVID-19 associated mucormycosis is difficult to treat and often presents in late stage. Uncontrolled diabetes, immunocompromised state, and steroid-induced immunosuppression were important risk factors. A close surveillance for early identification and initiation of treatment is mandatory. Repeated surgical debridement to clear the dead tissue is effective to control fungal load.

Keywords: Amphotericin B, Covid-19, invasive fungal sinusitis, mucormycosis

Introduction

Since the emergence of COVID-19 pandemic in March 2020, the medical fraternity all over the world have been constantly witnessing new paradigms of its clinical manifestations and other illnesses associated with this disease. Otolaryngologists have been involved in the management of COVID-19 at various levels and have to face new challenges. One such example was that of the higher than ever

number of mucormycosis infections, especially during the second wave of the COVID-19 pandemic.^{1,2} An exponential increase in the number of mucormycosis cases was seen in the entire country when compared to the rest of the world.³ A literature review on mucormycosis would reveal that several studies have been published so far, describing the different aspects of mucormycosis. Here, an attempt is made to revisit the clinical profile as well as the surgical strategies in the

Clinical Profile of Mucormycosis during the Second Wave of COVID-19 in a Tertiary Care Center in India

management of mucormycosis under the new scenario of COVID-19 pandemic. The different presentations of these cases, as encountered in a tertiary care center, would be highlighted. The aim is to study the clinical profile of mucormycosis as an effort to throw lights into a few risk factors and to present the details of the medical and surgical management of this disease.

Methods

This study was conducted at the Government Medical College Hospital Kozhikode, which is a tertiary care teaching center in India. An observational study design was followed. The total duration of the study was one year from May 2021 to April 2022, which included inpatient observation as well as a six-month post discharge follow-up of the patient. All patients who were covid positive with clinical and radiological evidence of mucormycosis, as well as a histopathological or microbiological evidence of mucormycosis, were included in the study. A convenience, purposive sampling method was employed and a written informed consent was obtained from all patients or from their primary care givers (in case of debilitated patients) before enrolment into the study. A scientific committee approval as well as ethics committee approval was obtained from the Institutional Ethics Committee of the Government Medical College Hospital Kozhikode (Ref No. GMC KKD /RP 2022/ IEC/14).

After the initial work-up, all patients had a CT scan and MRI of the nose and paranasal sinuses. All patients had a diagnostic nasal endoscopy done and samples were taken for KOH smear preparation, fungal culture, and histopathology examinations. The confirmed cases of mucormycosis were taken up for surgical debridement and Amphotericin B, which was already started empirically, would be continued.

Results

A total of 59 cases were enrolled in the study, mostly referred from peripheral hospitals. Most of the patients were males (67.8%), and the majority of patients belonged to the age group of 45-60 years. All of them were detected to be COVID-19 positive either during the admission or were previously infected within the past 2 months. About 59.3% had received the first dose of vaccination before the infection and one had received two doses of vaccination. Almost all the patients were diabetics, where 45.8 % had suffered from the disease for more than 10 years while six were recently detected as diabetics and were not on any medications. One patient with type 1 diabetes had been on insulin for the last 30 years. Hypertension was the most common coexisting disease (18.6%), followed by chronic kidney disease (16.9%) and coronary artery disease (8.5%). One patient had undergone renal transplant 10 years back for diabetic kidney disease. Most patients presented within an average

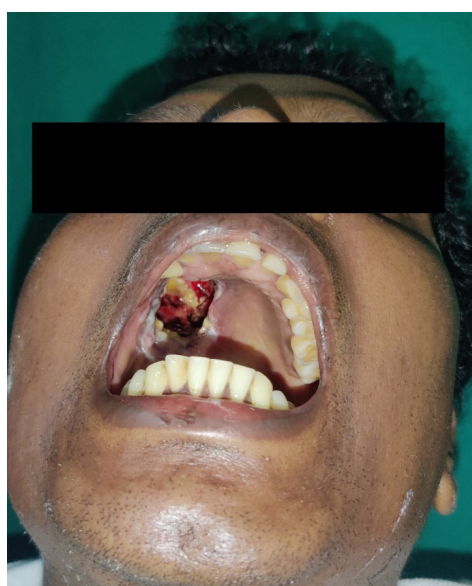

Fig 1. Palatal Perforation

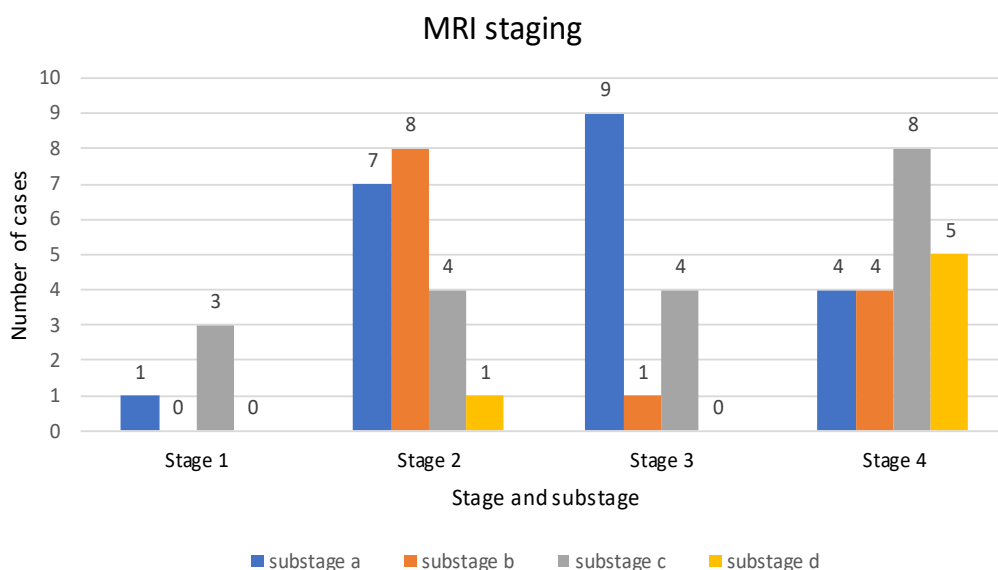


Fig 2. MRI staging based on the Honavar staging for COVID-19 associated rhino-orbital-cerebral mucormycosis cerebral mucormycosis¹

duration of 20.78±7.9 days from the day of onset of covid symptoms. Eleven patients were detected to experience an active covid infection at presentation, with symptoms of mucormycosis. About 48% patients had received intravenous corticosteroids as a part of the covid treatment.

Unilateral orbital and facial edema (28.8%) were the most common presenting symptom, followed by headache in 25.4% patients. In the majority of patients, the disease was lateralized to the right side; however, six patients experienced a bilateral involvement. The clinical examination revealed periorbital and facial edema as the primary signs in 44.1% patients, while nasal discharge was seen in 22 patients, of which 15 had a characteristic blackish discharge. Around 22% of these patients experienced a numbness of the face. A defective vision was noted in 20 patients of which 17 had only perception of light in the affected eye. Ptosis and ophthalmoplegia were noticed in 28.8% cases while proptosis was seen in 21 patients. There were 3 patients with a lower motor neuron type of facial nerve palsy and one patient presented with palatal perforation (Fig 1).

Blood investigations showed high levels of glycated hemoglobin with the HbA1c level of >7 in 54.2% of the patients. The ESR and

C-reactive protein (CRP) levels were elevated in all patients. In all cases referred to this center, computerized tomography (CT) scan of the nose and paranasal sinuses was the first radiological investigation done. An MRI scan with a gadolinium contrast was done in all, except in the 10 patients with chronic kidney disease. Based on these findings the patients were staged as per the Honavar staging for COVID-19 associated rhino-orbital-cerebral mucormycosis.⁴ Of the 35.5% patients who presented with a STAGE 4 disease and five (5) patients were in STAGE 4d, 8 in stage 4c, four (4) in STAGE 4a and 4b, respectively. The remaining 23.7% patients had a STAGE 3 and 33.8% had STAGE 2 disease (Fig 2).

Unilateral involvement of the paranasal sinuses was the most common finding noted. Most commonly involved sinuses were the ethmoids (89.8%), followed by the maxillary sinus (79.7%). Despite being a rare finding, isolated sphenoid sinus involvement was observed in one patient. Orbit involvement was seen in 57.6 %, of which 22% were an early involvement of the medial part of orbit as a result of the erosion of lamina papyracea. An involvement of the pterygopalatine fossa was noted in 31 patients (52.5%). Intracranial extension was seen in 19 patients, mostly in the form of cavernous sinus involvement mainly

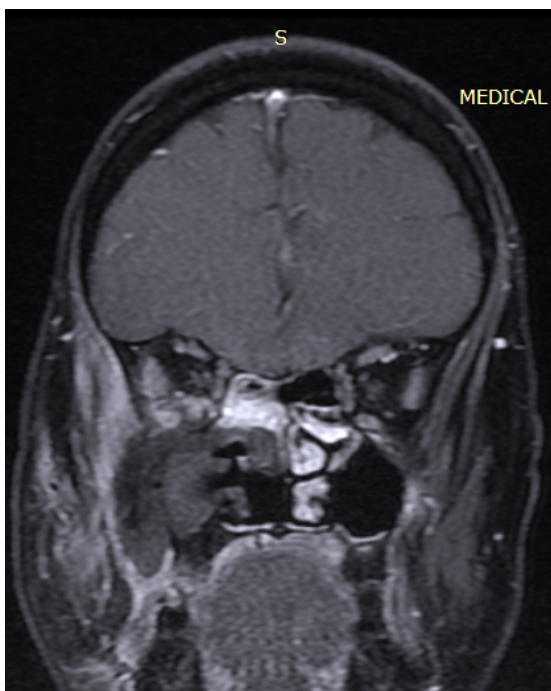


Fig. 3 Black Turbinate Sign

through the superior orbital fissure (78.9%). There were four cases of direct extension into the frontal lobe through the cribriform plate. Diffuse CNS involvement were seen in five (5) patients in the form of multiple infarcts, possibly embolic dissemination of the fungal materials. A diagnostic nasal endoscopy was done in all patients and 39 patients, showing the characteristically described black eschar in the nasal cavity. A discoloration of middle turbinate was noticed as the earliest finding in the study group. A nasal swab and a nasal mucosal biopsy were done. KOH mount gave a positive report in 69.5 % of patients. Fungal culture yielded *Rhizopus* in 64.4% of patients. Both KOH mount and fungal culture were found positive in 38.9 %. Histopathological examination and special staining were done in all patients and invasive fungal hyphae were demonstrated in 62.5% of patients. All the specimens were sent for microbiological and histopathological confirmation after surgical debridement was performed. In 14 cases, a coexisting invasive mucormycosis and aspergillus infections were present.

Patients were treated empirically using intravenous Amphotericin B based on clinical suspicion. Most patients underwent their first surgical debridement within a week of admission and were later followed up with

daily clinical progress with the ESR and CRP measurement repeated once every three days. In patients who did not show a significant improvement, further MRIs were performed to assess the need to undergo subsequent endoscopic examinations and debridement. Most common focus of residual disease during the re-examination was found to be at the pterygopalatine fossa. A repeat debridement had to be done in 86.4% of cases and 21 patients (35.5%) even had it done three times. Retrobulbar amphotericin injection for local control were given in four (4) patients, who had significant orbital involvement. Despite all these measures, orbital exenteration had to be carried out in nine patients for better clearance of fungal load. One patient experienced a frontal cerebritis which evolved into an abscess, which was drained by the neurosurgical team. Two patients underwent a high-resolution CT scan of the thorax in view of their persistent chest symptoms and were later found to have pulmonary involvement too.

The cumulative dose of the amphotericin B injection for most patients was 3gm (56 %), whereas 4 gm had to be given to 12 patients (20.3%) with stage 4 disease. The mean length of hospital stay was 27.7 days. A consolidation therapy with oral Posaconazole was started for patients on discharge. Among the patients in the study group, 13 (22%) succumbed to the disease during the hospital stay. Two patients had to be readmitted during the period of one month after the discharge but expired soon afterwards. One patient died as a result of his medical ailments within two months after the discharge. The remaining 43 patients showed a good clinical improvement during the follow-up period and were relatively symptom free at the end of the follow-up period.

Discussion

Mucormycosis is an uncommon and aggressive fungal infection that usually affects patients with an altered immunological system.⁵ This disease was first described by Furbingen in Germany (1876). Arnold Paltauf published the first case of disseminated mucormycosis in 1885.⁵ The prevalence of mucormycosis in India is estimated to be 0.14 cases per 1000 population, or approximately 80 times of the worldwide estimated rate.⁵ Among the different types of mucormycosis, the Rhino-orbito-cerebral form is considered the most common type, especially in patients with uncontrolled diabetes mellitus.⁶ Explanations

have been provided to explain the increased incidence of mucormycosis cases in diabetic patients. The most accepted theory is that persistent hyperglycemia causes an impaired chemotaxis affecting the phagocytic function of neutrophils. In addition, the ketoacidosis impairs the binding of iron to transferrin, thus increasing the amount of free iron in the body that in turn promotes fungal growth.⁷

A steroid-induced immunosuppression, as well as immune dysregulation associated with COVID-19 infection due to reduced numbers of CD8 and CD4 T lymphocytes, have also been considered as important factors in the current setting.⁸ A recent Indian study by Honavar *et al* reported a mean age of 51.9 years and a male preponderance of 71%.⁴ In a meta-analysis of 600 articles conducted by Jeong *et al* with 851 cases, the median age was 51 years and 63% patients were males.⁹ This study yielded a similar finding with the mean age being 52.7 years and a significant male predominance of 67.8%. In their meta-analysis, Jeong *et al* found diabetes mellitus as the most common underlying condition.⁹ They found the use of corticosteroids at the time of presentation as the most common predisposing factor (33%). All patients in this study were diabetics of which six of them were recently detected diabetics and almost 48% patients had received intravenous corticosteroids as a part of the covid treatment. The patients presented with features of mucormycosis on an average of 21 days from the day of onset of COVID infection. On the contrary, in a review of cases from 18 countries, Hoenigl *et al* reports a median duration of 10 days between COVID-19 and mucormycosis diagnosis.¹⁰ In patients without a concurrent covid infection, uncontrolled diabetes with ketoacidosis played a significant role. In this present study, headache and facial edema remain the earliest the presenting complaints, followed by proptosis, ptosis and visual disturbances. A complete loss of vision was seen in 4 patients (6.7%) due to a central retinal artery occlusion. Central retinal artery occlusion bears an incidence of 16-20% and is thought to be due to the vasculitis caused by the direct infiltration of the fungi in to the retinal artery.¹¹ Facial paresthesia was also commonly seen in patients with extensive orbital involvement. A black necrotic eschar seen on the palate or nasal mucosa were noted in 39 patients. MRI with gadolinium contrast assists in staging the disease and planning the extent of surgical debridement. The classical black turbinate sign described by Safder *et al* in MRI,¹² occurs due to the occlusion of small

vessels causing a lack of contrast enhancement of invaded mucosa (**Fig 3**).

Yield from a combination of diagnostic nasal endoscopy, microscopy and fungal culture were usually high. This warrants a close follow up of COVID-19 recovered patients with routine screening nasal endoscopies and guided swabs for early detection.

Treatments for mucormycosis of paranasal sinuses revolves around a combination of systemic antifungal therapy, the reversal of immunocompromised state and radical surgical debridement. A proper and rapid correction of the metabolic abnormalities along with the complete removal of all infected tissues gives a definite benefit.¹³ Time is a crucial factor as far as the treatment is concerned. Any inadvertent delay can significantly affect the treatment outcome. Treatment with liposomal or conventional Amphotericin B should be given as per recommendations, along with strict glycemic control and continuous renal function monitoring. There was a difficulty in procuring liposomal Amphotericin B for these patients, as there was a nation-wide shortage of Amphotericin B owing to the rapid increase in the number of mucormycosis cases. But somehow, the patients were put on a combination of liposomal or conventional Amphotericin B, depending on the availability. Surgical debridement needs to be done at the earliest. Surgical debridement slows the progression of the disease, reduces fungal load and it provides a specimen for culture. Several factors can delay the earliest surgical intervention. Even though the earliest surgical intervention was on the second day of admission, in few other cases the intervention had to be delayed due to an active covid infection in the patient. Even though the recommendations at that period was to defer the surgical debridement in COVID positive patients, an early intervention and emergency surgical debridement had to be done, to save few critically ill patients.

For the post procedure clinical assessment, patients had their routine ESR and CRP value estimation, which were helpful in marking the progress of the disease. A repeat MRI with contrast was taken on noticing any clinical deterioration or increasing levels of the inflammatory markers. The subsequent scan helped in picking up any residual disease in the orbit and pterygopalatine fossa. These areas are usually neglected during the initial surgical debridement because on visualizing an intact posterior wall of maxilla and lamina, the surgeon hopes that the disease would

not have breached the intact bony wall. Even though Plowes *et al* mentions 100% involvement of the pterygomaxillary fissure in their series of five patients, the present study found the area to be involved in 52.5% (31 patients).¹⁴

In these cases, complete clearance of fungal load is mandatory; hence, a good exposure of the surgical field is essential. For this reason, a modified endoscopic Denker's method, as well as maxillary posterior wall removal, devitalized tissue debridement in the pterygopalatine fossa, and pterygoid base drilling would be a good option to ensure a reasonably good clearance. Even though there is no clear-cut evidence, topical antifungal therapy is primarily used adjunctively in invasive fungal sinusitis.¹⁵ Considering the relatively low systemic absorption, topical amphotericin gel for local application was used in some cases, at surgical sites where the complete clearance was still doubtful. While managing the orbital counterpart of this disease, cosmetic outcome becomes an important aspect and hence a trial with retrobulbar amphotericin injections should always be considered first. In this series, a retrobulbar amphotericin injection was given in 4 patients. A meticulous orbital debridement helps in removing all devitalized orbital tissues and gives an option of preserving the globe. It helps in eliminating the fungal load and can very well prevent a dreaded intracranial extension. But in a worsening clinical scenario, with cavernous sinus thrombosis, an orbital exenteration is warranted so as to avoid an intracranial involvement. Plowes *et al.* in their study has considered orbital apex syndrome and cavernous sinus thrombosis as

the only criterion for an orbital exenteration.¹⁴ Seiff *et al* considered removing the infected orbital tissues conservatively and irrigating the remaining tissue with a solution of Amphotericin B.¹⁶ They claimed that their technique avoided an orbital exenteration in most cases. Despite doing a thorough orbital debridement, using local Amphotericin B wash and retrobulbar injections in selected cases, an orbital exenteration had to be done in 9 cases.

In a study by Jeong *et al*,⁹ the overall mortality was 46% whereas in the review by Hoenigl *et al*¹⁰ mortality was reported in 37% cases. In this series, the mortality was only 27 % which was possible due to the prompt response of the surgical team in clearing the fungal load along with maximal medical therapy. Hence a close surveillance post covid, early recognition of symptoms and early initiation of treatment can drastically improve the prognosis in patients. In conclusion, mucormycosis cases spiked up in India in association with COVID 19 infection and added to the disease morbidity and mortality. Uncontrolled diabetes, immunocompromised state and steroid-induced immunosuppression were the important risk factors for COVID-19 associated mucormycosis. Routine nasal endoscopies, meticulous sampling and an MRI with gadolinium contrast in suspicious cases will help in accurate diagnosis. A thorough monitoring of immunocompromised state and an early initiation of liposomal amphotericin B therapy is indicated, along with repeated surgical debridement till a complete clearance of dead tissue is obtained. These measures can help in reducing the mortality associated with this disease to a great extent.

References

1. Pal R, Singh B, Bhadada SK, Banerjee M, Bhogal RS, Hage N, *et al.* COVID-19-associated mucormycosis: An updated systematic review of literature. *Mycoses*. 2021;64(12):1452–9.
2. Hoenigl M, Seidel D, Carvalho A, Rudramurthy SM, Arastehfar A, Gangneux JP, *et al.* The emergence of COVID-19 associated mucormycosis: a review of cases from 18 countries. *Lancet Microbe*. 2022;3(7): e543–52.
3. Muthu V, Rudramurthy SM, Chakrabarti A, Agarwal R. Epidemiology and pathophysiology of COVID-19-associated mucormycosis: India versus the rest of the world. *Mycopathologia*. 2021;186(6):739–54
4. Sen M, Honavar SG, Bansal R, Sengupta S, Rao R, Kim U, *et al.* Epidemiology, clinical profile, management, and outcome of COVID-19-associated rhino-orbital-cerebral mucormycosis in 2826 patients in India – Collaborative OPAI-IJO Study on Mucormycosis in COVID-19 (COSMIC), Report 1. *Indian J Ophthalmol* 2021;69(7):1670–92.
5. Skiada A, Pavleas I, Drogari-Apiranthitou M. Epidemiology and diagnosis of mucormycosis: an update. *J Fungi (Basel)*. 2020;6(4):265.
6. Chakrabarti A, Singh R. Mucormycosis in India: unique features. *Mycoses*. 2014;57 Suppl 3:85–90.
7. Balai E, Mummadi S, Jolly K, Darr A,

Clinical Profile of Mucormycosis during the Second Wave of COVID-19 in a Tertiary Care Center in India

- Aldeerawi H. Rhinocerebral mucormycosis: a ten-year single centre case series. *Cureus*. 2020;12(11):e11776. Published 2020 Nov 29.
8. Gangneux JP, Bournoux ME, Dannaoui E, Cornet M, Zahar JR. Invasive fungal diseases during COVID-19: we should be prepared. *J Mycol Med*. 2020;30(2):100971.
 9. Jeong W, Keighley C, Wolfe R, Lee WL, Slavin MA, Kong DCM, Chen SC. The epidemiology and clinical manifestations of mucormycosis: a systematic review and meta-analysis of case reports. *Clin Microbiol Infect*. 2019;25(1):26–34.
 10. Hoenigl M, Seidel D, Carvalho A, Rudramurthy SM, Arastehfar A, Gangneux JP, *et al*. The emergence of COVID-19 associated mucormycosis: a review of cases from 18 countries. *Lancet Microbe*. 2022;3(7):e543–52.
 11. Kamath S, Kumar M, Sarkar N, Ahmed T, Sunder A. Study of profile of mucormycosis during the second wave of COVID-19 in a tertiary care hospital. *Cureus*. 2022;14(1):e21054.
 12. Safder S, Carpenter JS, Roberts TD, Bailey N. The “Black Turbinate” sign: An early MR imaging finding of nasal mucormycosis. *AJNR Am J Neuroradiol*. 2010;31(4):771–4.
 13. Skiada A, Lass-Floerl C, Klimko N, Ibrahim A, Roilides E, Petrikos G. Challenges in the diagnosis and treatment of mucormycosis. *Med Mycol*. 2018;56(suppl_1):93–101.
 14. Plowes Hernández O, Prado Calleros HM, Soberón Marmisolle Daguerre GS, Sadek González A. Rhino-orbito-cerebral mucormycosis. Management strategies to avoid or limit intracranial affection and improve survival. *Acta Otorrinolaringol Esp*. 2015;66(6):348–52.
 15. Luk LJ, DelGaudio JM. Topical drug therapies for chronic rhinosinusitis. *Otolaryngol Clin North Am*. 2017;50(3):533–43.
 16. Seiff SR, Choo PH, Carter SR. Role of local amphotericin B therapy for sino-orbital fungal infections. *Ophthalmic Plast Reconstr Surg*. 1999;15(1):28–31.